

# Peripheral Nerve Stimulation for Unremitting Ophthalmic Postherpetic Neuralgia

---

Edwin Dunteman, MD, MS

*A. & A. Pain Institute, St. Louis, Missouri*

## ■ ABSTRACT

Postherpetic neuralgia (PHN) is a common cause of chronic pain in the elderly. Opioids and adjunctive analgesics such as antidepressants and anticonvulsants effectively reduce discomfort in many patients, while others have pain that remains resistant to all forms of therapy. Spinal cord stimulation has shown promise for severe truncal and extremity PHN, but has no impact on neuralgias of cranial nerve origin. Peripheral nerve stimulation has been described for such problems as chronic regional pain syndrome, but to date

has not been reported for cranial nerve syndromes. This article describes the cases in which an 86-year-old man and a 76-year-old woman with intractable PHN of greater than 6 and 4 years, respectively, were effectively treated with peripheral nerve stimulation of the ophthalmic division of the trigeminal nerve. ■

**KEY WORDS:** herpes zoster, neuromodulation, peripheral nerve stimulation, post herpetic neuralgia, shingles.

## INTRODUCTION

Herpes Zoster from the Varicella Zoster Virus (VZV), or “shingles” and post herpetic neuralgia (PHN) remain all too common maladies affecting primarily senior citizens. With a lifelong prevalence approaching 20%, and an incidence that increases with age; VZV represents a major public health issue in the geriatric population (1–3). An unfortunate proportion of the elderly develops the dreaded prolonged pain syndrome of PHN, which may persist for months to years after the shingles rash heals. Many patients with PHN get

either inadequate or no treatment whatsoever for their often intractable pain (4).

Promising new clinical investigations of anti-convulsant drugs like gabapentin have advanced the treatment of multiple neuropathic pain syndromes, including PHN (4). Unfortunately, a significant percentage of patients have continued unremitting pain, despite treatment with opioids, antidepressants, anticonvulsants, as well as a wide variety of “off-label” and complementary therapies (1,3,5,6). Neuromodulation, using spinal cord stimulation (SCS), has offered hope to many who failed conservative PHN management (7,8). Unfortunately, not all regions of the body are amenable to spinal stimulation. Alternatively, peripheral nerve stimulation (PNS) has been proven useful for many neuropathic syndromes in the extremities (8–11). PHN of the trigeminal nerve ophthalmic division, primarily the supraorbital and supratrochlear nerves (Figure 1), is a common condition,

Reprint requests to Edwin Dunteman, MD, MS, A&A Pain Treatment Center, St. Louis, MO 63141.

© 2002 International Neuromodulation Society, 1094-7159/02/\$15.00/0  
*Neuromodulation, Volume 5, Number 1, 2002 32–37*

yet not treatable currently by contemporary neuromodulation techniques, other than transcutaneous electrical nerve stimulation (TENS). Peripheral nerve stimulation for pain of craniofacial neuralgias, such as PHN has not yet been reported. This report describes the cases where peripheral nerve stimulation technique significantly reduced pain in two patients with chronic ophthalmic division postherpetic neuralgia.

## METHODS

### Patient 1

An 86-year-old male who had herpes zoster ophthalmicus onset 10/92 involving the left side of his face and scalp had failed multiple treatment approaches. Various opioid analgesics, including propoxyphene, codeine, hydrocodone, tramadol, and sustained release morphine, were of limited benefit. Adjunctive analgesics, including amitriptyline, nortriptyline, doxepin, mexilitine, phenytoin, carbamazepine, lamotrigine, and gabapentin, added only mild benefit to opioid therapy. Topical EMLA, lidocaine, and aspirin compounds also failed to provide significant relief.

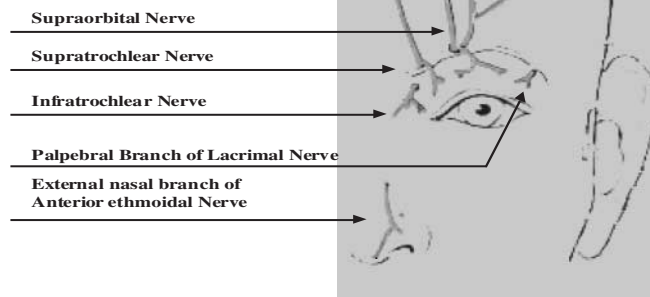
The patient described his pain as burning, stabbing, and aching in nature, at a near constant 6–8 on a 0–10 Visual Analog Scale (VAS). He also reported that he was never pain-

free. Allodynia was noted around the left eye, forehead, as well as the left frontal and parietal scalp regions that would worsen significantly in response to even a mild breeze. He was unable to comb his hair, or take a shower without severe worsening of his pain. Regional blockade of the supraorbital and supratrochlear nerves with bupivacaine on three occasions produced complete resolution of the pain for periods ranging from 12 to 24 h.

Due to the repetitive responses to peripheral nerve blockade, as well as consistent treatment failures to exhaustive treatment trials, this patient was felt to be a reasonable candidate for a trial of novel peripheral nerve stimulation. Risks, potential benefits, and the off-label nature of the treatment approach were explained to the patient; and he consented to a trial supraorbital and supratrochlear peripheral nerve stimulation lead placement.

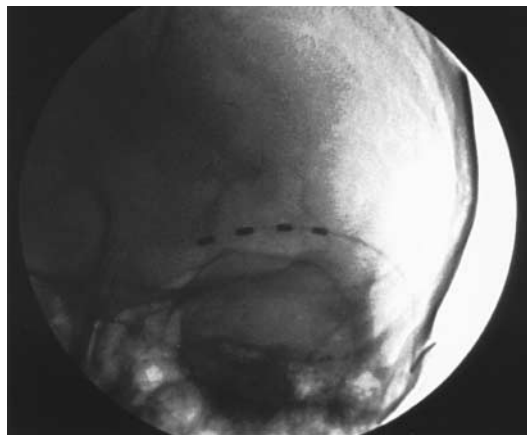
The regions of the head, face, and neck involved with percutaneous electrode placement and tunneling were sterilely prepared and draped. A 1% lidocaine skin wheal was placed approximately 5 mm lateral to the involved eyebrow, without allowing spread of local anesthetic to the nerves to be stimulated. The introducing Tuohy needle was adapted to allow an arching trajectory above the orbital ridge. Following adequate sedation with propofol, the introducing needle is passed through the skin

### Facial Innervation From the Ophthalmic Division of the Trigeminal Nerve



**Figure 1.** Facial innervation from the ophthalmic division of the trigeminal nerve.

wheel and directed in a supra-periosteal tissue plane over the eyebrow in a semilunar path, cephalad to the orbicularis oculi, to end slightly above the glabella in the cranial midline. The noncutting Tuohy needle-tip prevents laceration of local vascular and neural structures. A Pisces Quad-4 spinal cord stimulator lead (Medtronic, Minneapolis, MN) was passed through the needle, which was then withdrawn, leaving the electrode arched over the eyebrow and adjacent to the supraorbital and supratrochlear branches of the trigeminal nerve. (Figure 2) The patient was allowed to become more alert to allow testing and positioning of the lead. Using a screening extension connection, the lead was positioned to produce a paresthesia in the distribution of the supraorbital and supratrochlear nerves, where the patient experienced his pain. Following further sedation, the original puncture site was expanded with a small incision to allow the electrode to be secured to the periosteum. After adequate local anesthesia, a series of sequential passes of the Tuohy needle allowed tunneling the electrode to suprascapular region where a subcutaneous pocket allowed connection of the electrode to an externalized trial extension lead. During a 5-day trial period, the patient experienced significant benefit including decreased pain and medication requirement, as well as improved sleep and mood. At the end of the trial, he requested permanent implantation. The implan-



**Figure 2.** Left supraorbital stimulator lead on 86-year-old male (Patient 1).

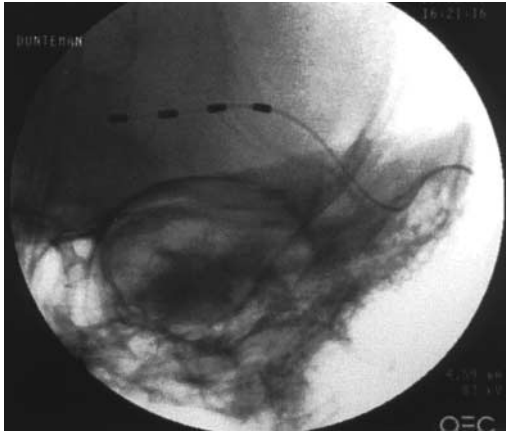table pulse generator (IPG) unit was placed in the left pectoral region, and connected to the stimulator lead via a permanent tunneled connection.

### Patient 2

A 76-year-old woman with severe PHN of the left ophthalmic nerve for greater than four years was also evaluated for the treatment protocol after she had failed several treatment approaches. Multiple antidepressants, anticonvulsants, topical agents, as well as several opioid analgesics including methadone 15 mg/day and oxycodone 15–20 mg/day failed to provide adequate pain relief. She nearly constantly carried an ice pack on her head. Following a protocol identical to Patient 1, she tolerated two trial blocks of the ophthalmic branches of the trigeminal nerve with bupivacaine, which produced near complete resolution of her pain. A subsequent trial placement of a supraorbital stimulator lead (Figure 3) greatly improved the burning and aching components of her pain. After a successful 5-day trial the IPG was implanted permanently.

### RESULTS

For Patient 1, during the trial and ongoing postimplantation period (currently three years) the patient described complete resolution of the burning pain above the eye and in the forehead region. Mild aching remained in the scalp region at a 4/10 VAS level. A residual pain under the left eye remained, but was 40–60% improved over prestimulator pain reports. Allodynia was greatly improved over the forehead and scalp, with only mild discomfort reported to touch over the parietal scalp region. Intermittent stimulation provided prolonged pain relief for several hours after the stimulator was turned off. The patient was able to sleep through the night with minimal discomfort even after turning off the stimulator. He was also able to greatly reduce his hydrocodone to 1–2 tablets every 2–3 days, and stop topical agents completely. He was also able to tolerate hair combing and direct shower contact to the scalp. Stimulator parameters with best coverage of pain included a bipolar configuration, with all electrodes as negative and the



**Figure 3.** Supraorbital stimulator on 76-year-old female (Patient 2).

IPG as positive, pulse-width 390  $\mu\text{sec}$ , at a frequency of 50 pulses/sec. Amplitude was adjusted by the patient, depending on discomfort, and would range from “off” to 3 V. If the rate was increased above 110 pulses/sec., the patient would report an uncomfortable itching or pressure sensation.

Patient 2 is approaching three years of use with the supraorbital stimulator. While she had difficulties using the 0–10 VAS pain scoring, she has been able to stop using daily ice packs, discontinue methadone, and diminish her oxycodone use by greater than 50%. A recent exhaustion of the IPG unit lead to her resuming the daily ice packs, methadone, and increased use of oxycodone. Replacement of the IPG unit lead to her once again discontinuing the ice packs, methadone, and diminishing the opioids to prerenal levels. The burning sensations are well controlled, but she often complains of an itching component near the side of her eye. Increasing the pulse width to 420  $\mu\text{sec}$ , with a lower rate (< 55 pulses/sec) seems to limit the itching sensation. For this patient, faster pulse rates (> 100) predictably produce a worsening of the itching sensation. She prefers an amplitude range of 1–5 V, and may sleep with the unit off.

## DISCUSSION

Post herpetic neuralgia has been called the most common cause of intractable pain in the elderly and the leading cause of suicide in chronic pain

patients over the age of 70 (6). In a VZV outbreak the dormant varicella virus is reactivated within the dorsal root or extramedullary ganglia to cause neuronal inflammation and necrosis, characterized by intense lymphocytic infiltration, endothelial proliferation, focal hemorrhage, and sheath inflammation (12,13). The infection continues into the sensory nerve and is transported to the nerve endings, where it is released into the cutaneous region, where the characteristic lesions erupt. Microscopically, intense necrotizing inflammation of the dorsal root ganglion, dorsal horn, and peripheral nerves is seen, as well as peripheral demyelination and large fiber destruction (13). Preferential loss of the modulatory large fibers leaves loss of inhibition to the nociceptive small fibers, and enhanced sensitivity to even light touch. PHN is a form of deafferentation pain with both central and peripheral mechanisms of dysfunction and degeneration (1,2,5,13,14). The ophthalmic branch of the trigeminal nerve is the most frequently involved site for HZ in the elderly, followed by thoracic dermatomes, and therefore one of the most common sites of PHN in the aged (1,2).

The overall incidence of prolonged pain after HZ lesion healing (PHN) is 18–35% of all HZ patients, and increases with age, exceeding 75% in patients older than 80 (1). PHN is common following herpes zoster ophthalmicus, and extremely common in patients with coexisting diabetes. While 50% of patients eventually have resolution of their pain within three months, and 80% within five years, 2% may have pain for greater than five years (1–3).

The pain of PHN is typically unilateral and dermatomal, and overlies the region involved with the shingles rash. The region may be insensitive to pinprick and local heat or cold. Mild, normally nonpainful stimuli to this area may trigger pain (allodynia). Intense pain, triggered by the light touch of clothing, leads the patients to minimize or forego clothing, forcing many to stay home. Spontaneous pain is described as burning, throbbing, stabbing, shooting, sharp, or aching. This discomfort may be continuous with fluctuating intensity, or paroxysmal, worsened by cold weather or stress (1).

There is no known, consistently reliable, definitive treatment that provides permanent

relief of established PHN (3). Early antiviral therapy may shorten duration of viremia and prevent persistent infection during the first year of neuralgia, but of no value thereafter (15). Opioid analgesics, antidepressants, antiarrhythmics, topical agents, and more recently anticonvulsants are potential pharmacologic approaches to treating the pain of PHN (1,3–5). Interestingly, a recent clinical study found that the majority of patients enrolled were receiving no therapy whatsoever for pain greater than 4 on a 0–10 VAS scale (4). Interventional approaches, such as somatic or sympathetic blockade have shown promise if used during HZ or early in PHN, but no long-term benefit in established PHN (16). In severe cases where all therapies have failed, SCS has been useful to reduce pain from PHN of truncal or extremity locations (7). Unfortunately, PHN involving the cranial nerves isn't amenable to standard SCS techniques. Other peripheral neuropathic pain syndromes such as chronic regional pain syndrome (CRPS; types I and II), brachial plexopathy, and multiple mononeuropathies have responded to direct peripheral nerve stimulation (PNS) (9–11,17–19). Furthermore, many new PNS targeting methodologies have also been recently described (20–26). Occipital neuralgia is a peripheral neuropathy that may be analogous to PHN of the trigeminal nerve ophthalmic division, in that it encompasses a dermatome that involves the head, and may respond to direct peripheral nerve stimulation (19,22,26–28). In fact, occipital nerve stimulation has become a well-recognized and accepted treatment for occipital neuralgia and various intractable headache syndromes (6,27,28). As with other peripheral nerves, local anesthetic blockade appears to be prognostic for response to PNS (10).

For PNS, the intensity, frequency, and pulse width of stimulation is adjusted so that low-threshold sensory axons ( $A\beta$ ) are preferentially activated, producing a tingling sensation in the involved area (9,10). As with spinal cord stimulation, proposed mechanisms of PNS include modulation of various neurotransmitters (GABA, VIP, CCK, somatostatin, substance P, neurotensin, endogenous opioids, and other amines) and the gating of nociceptive input (11,29). Peripheral activation of large myelinated nerve fibers is

believed to interrupt the transmission of nociception via activation of inhibitory circuits within the dorsal horn (11). Another proposed mechanism is that PNS produces a nondecipherable code that, like gating, jams sensory input into the CNS (10). A recent review of the literature and requests to the manufacturers of neurostimulators failed to find evidence of PNS techniques for cranial nerve neuropathies. Ophthalmic branches of the trigeminal nerve offer unique treatment possibilities for PNS techniques, due to their accessibility and primarily sensory function. Since the supraorbital and supratrochlear nerves are the most common site for PHN in the elderly, new advances, such as this treatment technique, may offer hope for a significant population of people with this form of chronic pain.

## CONCLUSION

The report of these two cases demonstrates that peripheral nerve stimulation techniques may be useful for PHN at sites not amenable to existent spinal cord stimulation techniques. Clearly, ongoing investigation of this technique is required to confirm, as well as to chronicle its effectiveness as a technique of neuromodulation treatment of recalcitrant PHN.

## ACKNOWLEDGMENT

The author thanks Kenneth Aló MD for his editorial review, advice, and critique that greatly improved the quality of this paper.

## REFERENCES

1. Mohamed SA, Carr DB. Pain during herpes zoster (shingles) – and long after. *Pain: Clinic Updates* 1994;2:1–4.
2. Ragozzino MW, Melton LJ, Kurland LT *et al.* Population-based study of herpes zoster and its sequelae. *Medicine (Baltimore)* 1982;61:310–316.
3. Robinson PN, Fletcher N. Postherpetic neuralgia. *J R Coll Gen Pract* 1986;36:24–28.
4. Rowbotham M, Harden N, Stacey B, Berstein P, Magnus-Miller L. Gabapentin for treatment of postherpetic neuralgia. A randomized controlled trial. *JAMA* 1998;280:1837–1842.

5. Dworkin RH, Portenoy RK. Pain and its persistence in herpes zoster. *Pain* 1996;67:241–251.
6. Weiner RL, Reed KL, Aló KM. Peripheral stimulation for occipital neuralgia. Abstracts of the AANS (Journal of Neurosurgery), Boston, MA. December. 1999.
7. Shimoji K, Hokari T, Tatsuhiko K, *et al.* Management of intractable pain with percutaneous epidural spinal cord stimulation: Differences in Pain-relieving effects among diseases and sites of pain. *Anesth Analg* 1993;77:110–116.
8. Urban BJ, Nashold BS. Combined epidural and peripheral nerve stimulation for relief of pain. Description of technique and preliminary results. *J Neurosurg* 1982;57:365–369.
9. Hasenbusch SJ, Stanton-Hicks M, Schoppa D, Walsh JG, Covington EC. Long-term results of peripheral nerve stimulation for reflex sympathetic dystrophy. *J Neurosurg* 1996;84:415–423.
10. Heavner JE, Racz G, Diede JM. Peripheral nerve stimulation: current concepts. In: Waldman S, Winnie A. eds. *Interventional Pain Management* Philadelphia: W.B. Saunders, 1996:423–425.
11. Stanton-Hicks M, Salamon J. Stimulation of the central and peripheral nervous system for the control of pain. *J Clin Neurophysiol* 1997;14:46–62.
12. Friedman AH, Nashold BS, Ovelman-Levitt J. Dorsal root entry zone lesions for the treatment of postherpetic neuralgia. *J Neurosurgery* 1984;60:1258–1262.
13. Ghatak NR, Zimmerman HM. Spinal ganglion in Herpes zoster. *Arch Pathol* 1973;95:411–415.
14. Winnie AP. Panel on herpes zoster. *American Society of Regional Anesthesia 8th Annual Meeting Orlando, Fl, March.*, 1983.
15. Surman OS, Flynn T, Schooley RT, *et al.* A double blind, placebo controlled study of oral acyclovir in post-herpetic neuralgia. *Psychosomatics* 1990;31:287–292.
16. Winnie AP, Hartwell PW. Relationship between time of treatment of acute herpes zoster with sympathetic blockade and prevention of post-herpetic neuralgia: Clinical support for a new theory of the mechanism by which sympathetic blockade provides therapeutic benefit. *Reg Anesthes* 1993;18:277–282.
17. Lou L. Uncommon areas of electrical stimulation for pain relief. *Curr Rev Pain* 2000;4:407–412.
18. Iacono RP, Linford J, Sandyk R. Pain Management after lower extremity amputation. *Neurosurgery* 1987;20:496–500.
19. Waisbrod H, Panhans C, Hansen D, Gerbershagen H. Direct nerve stimulation for painful peripheral neuropathies. *J Bone Joint Surg (Br)* 1985;67:470–472.
20. Aló KM. Lead positioning and programming strategies in the treatment of complex pain. *Neuro-modulation* 1999;2:165–170.
21. Aló KM. Radiologic considerations for neurostimulation lead placement: Lumbar and sacral selective lead placement. In: Best TM, ed. *Fluoroscopy manual for pain management*. Evergreen, CO: Pain Management Innovations, 2000:31–37.
22. Aló KM, Holsheimer J. Review. New trends in neuromodulation for the management of neuropathic pain. *J Neurosurg* 2001; in press.
23. Aló KM, McDonald J. Pelvic and perineal pain of urologic origin. In: Loeser J, ed. *Bonica's Management of Pain*, 3rd edn. Philadelphia: Lippincott Williams & Wilkins, 2001:1454.
24. Aló KM, Yland MJ, Redko V, Feler C, Naumann C. Lumbar and sacral nerve root stimulation (NRS) in the treatment of chronic pain, a novel anatomic approach and neurostimulation technique. *Neuromodulation* 1999;2:23–31.
25. Aló KM, Yland MJ, Feler C, Oakley J. A study of electrode placement at the cervical and upper thoracic nerve roots using an anatomic trans-spinal approach. *Neuromodulation* 1999;2:222–227.
26. Weiner RL, Aló KM. C2 neurostimulation for intractable occipital neuralgia. Abstracts: The 9th World Congress for the Study of Pain (IASP); Vienna, Austria. August. 1999.
27. Weiner RL, Aló KM, Feler CA, *et al.* Occipital stimulation for the treatment of chronic headache. Abstracts of the Fourth Congress of the International Neuromodulation Society and Functional Electrical Neurostimulation Society. Lucerne, Switzerland. August. 1998.
28. Weiner RL, Reed KL. Peripheral neurostimulation for control of intractable occipital neuralgia. *Neuromodulation* 1999;2:217–221.
29. Takahashi, Nomura S, Tomita K, Matsumoto T. Effects of peripheral nerve stimulation on the blood-flow of the spinal cord and the nerve root. *Spine* 1998;13:1278–1283.