

Retrospective Analysis

Occipital Neuromodulation: A Surgical Technique with Reduced Complications

Thomas P Pittelkow, DO, MPH, Gabriel L Pagani-Estévez, MD, Bradford Landry, DO, MSPT, Matthew J Pingree, MD, and Jason S Eldrige, MD

From: Mayo Clinic Minnesota,
Rochester, MN

Address Correspondence:
Gabriel L Pagani-Estévez, MD
Mayo Clinic Minnesota
200 First Street SW
Rochester, MN 55905
E-mail:
paganiestevez.gabriel@mayo.
edu

Disclaimer: There was no external funding in the preparation of this manuscript. Conflict of interest: Each author certifies that he or she, or a member of his or her immediate family, has no commercial association (i.e., consultancies, stock ownership, equity interest, patent/licensing arrangements, etc.) that might pose a conflict of interest in connection with the submitted manuscript.

Manuscript received: 01-16-2016
Revised manuscript received:
04-18-2016
Accepted for publication:
04-28-2016

Free full manuscript:
www.painphysicianjournal.com

Background: Occipital neuromodulation is a promising treatment modality for refractory headache, but lead migration remains a frequent surgical complication.

Objectives: The primary objective was to identify surgical techniques that may minimize adverse events, particularly lead migration. We hypothesized that a surgical technique employing 2-point anchoring of stimulator leads designed to provide a tension-relief loop and the use of ultrasound for lead placement would decrease the complication rate.

Study Design and Setting: A retrospective analysis was performed through electronic medical record chart review in a tertiary referral center.

Methods: Institutional Review Board (IRB) approval was obtained. Eighteen patients had a trial and subsequent permanent occipital nerve stimulator (ONS) implantation between 2004 and 2011 and were included. Adverse events were recorded and efficacy outcome variables analyzed for significance.

Results: The cohort was a median (IQR) 45 (37 – 58) in age and 9 (50%) were women. Tension-relief loops placed via a 2-point anchoring technique and ultrasound use for occipital lead placement were evident in 16 (89%) and 13 (72%), respectively. There was one (6%) clinically insignificant lead position change, not definitively a lead migration, which could have been an artifact of fluoroscope positioning. Adverse events included one (6%) battery malfunction, one (6%) lead malfunction, and 2 (12%) post-implantation infections. Following ONS, there were significant reductions in numeric rating scale (NRS) pain scores from a median (IQR) of 9.5 (8.25 – 10) to 2.5 (1 – 4.75) ($P < 0.0001$), headache days per week from 7 (7 – 7) to 1.5 (0.375 – 1.75) ($P = 0.0005$), and the number of daily headache medication from 3 (2.25 – 4) to 2.5 (2 – 3.75) ($P = 0.0112$).

Limitations: Limitations include retrospective study design, investigator bias, and non-standardized intervals of headache burden assessment.

Conclusions: In ONS, utilization of a 2-point anchoring technique with a tension-relief loop may significantly minimize the risk of lead migration, based on the absence of definitive lead migration in our series. Ultrasound use may improve the anatomic accuracy of lead placement with the possibility of improved efficacy. ONS was associated with significantly decreased headache pain, frequency, and medication use.

Key words: Occipital neuromodulation, occipital nerve stimulation, surgical technique, lead migration, tension-relief loop

Pain Physician 2016; 19:E1005-E1012

Refractory headache disorders have an estimated worldwide prevalence of 4% and represent a major source of suffering, disability, and opportunity cost (1). Migraine, a major subset of refractory headaches, ranks as the eighth leading cause of disability worldwide, and every year, 2.5% of episodic migraine patients transform to chronic migraines (CM) (2). CM can affect up to 3.2 million Americans based on global prevalence rates (3). The American Migraine Prevalence and Prevention (AMPP) study demonstrated that over 12% of Americans suffer from chronic migraine, and despite their nearly universal use of daily preventive or abortive medication, many still reported significant pain and functional disability (4). In 2008, nearly 4.5% of all emergency department visits listed headache or migraine as the first or second diagnoses, with some patients requiring inpatient admission for pain control (5). Headaches were responsible for a health care costs in excess of \$408 million in 2008. Successful alternative therapy for refractory headache remains a greatly unmet need.

Occipital neurostimulation (ONS) for refractory headache remains the most promising of these alternative treatment modalities and has been a successful intervention for years, with observations of efficacy spanning millennia. The Greco-Roman physician Galen espoused using the shock of an electric torpedo fish applied to the head to treat severe headache in the second century, A.D. (6). More recently, a systematic review and meta-analysis of ONS in CM patients analyzed 5 randomized controlled trials (RCTs) and 7 case series (7). ONS decreased prolonged moderate or severe headache days per month by a mean of 2.59 in excess of sham stimulation, which itself decreased headaches by 2 to 4 days per month. While measures of functional disability, responder rate, quality of life, and treatment satisfaction seemed to favor ONS, heterogeneity in reporting precluded assessment of statistical significance in the meta-analysis.

The most recent double-blinded RCT published after the meta-analysis studied 157 CM patients and randomized the patients to either sham or ONS for the first 12 weeks (8). After 12 weeks, all patients received stimulation for a total study duration of 52 weeks. The ONS intention-to-treat (ITT) group analysis found a reduction of headache days per month of 6.7 ± 8.4 ($P < 0.001$). Fifty-nine point five percent of patients reported a 30% reduction of headache days or pain intensity while 47.8% reported similar reductions of 50%. MIDAS and Zung PAD scores, measures of disability, were also

significantly reduced by ONS. At 52 weeks, 65.4% of the ITT group reported good or excellent headache relief, 68.4% reported improved quality of life, and 68% reported being satisfied or very satisfied with the procedure.

Although the most robust evidence exists for CM, smaller studies have also documented ONS efficacy in other headache disorders, including occipital neuralgia and the trigeminal autonomic cephalalgias (cluster headache, hemicrania continua, paroxysmal hemicranias, and SUNCT/SUNA). The European Headache Federation recommends ONS consideration in medically refractory headache patients (9) and the Congress of Neurological Surgeons provides AANS/CNS level III recommendation for consideration of ONS in medically refractory occipital neuralgia patients (10).

Despite these promising measures of efficacy and patient satisfaction, ONS has been plagued by high complication rates, most commonly lead migration, often resulting in surgical revision and the potential for further complications. The reported lead migration incidence rate has been as high as 67%, with the largest migraine RCTs reporting lead migration rates of 13.9% to 24% (7). Suggested efforts to reduce lead migration have included the use of circular coils when placing lead extension to create strain-relief loops and firm anchoring to the epifascial plane (9,11). Heterogeneity and at times incomplete reporting of surgical technique have precluded a measured analysis of methods to mitigate lead migration. A paucity of well-designed studies investigating lead migration rates complicates matters further.

The purpose of this study was to demonstrate our current ONS surgical technique and to report clinical outcome variables in a retrospective fashion. The primary objective was to identify variations in surgical technique, specifically anchoring of leads and the use of ultrasound for lead placement, and to report associated adverse events such as post-operative lead migration or surgical revision. The secondary objective was to examine documented, patient reported outcomes of preoperative and postoperative pain levels using the numeric rating scale (NRS) pain scale, headache days per week, and the number of pain medications used to treat headache.

METHODS

Patient selection

The Institutional Review Board (IRB) approved

a proposal for a retrospective chart review. All patients identified were diagnosed with primary, medically intractable headaches refractory to conventional treatments by the Headache Disorder Clinic and were referred to the Pain Medicine Clinic for ONS consideration. Eighteen patients had ONS trial and implantation between 2004 and 2011 and were included for study. Patients with only stimulation trials were excluded.

Surgical Technique

Following informed consent, each patient was brought to the operating theater, placed in the prone position, and provided with monitored anesthesia care. Fluoroscopy was used to identify the C1 vertebral body in the anteroposterior plane and to mark its suboccipital location on the skin. The skin was cleansed and draped in sterile fashion. Lidocaine 1% with 0.25% bupivacaine mixed in a 1:1 ratio with 1:200,000 epinephrine was then used to anesthetize the skin and subcutaneous tissue. A linear 12 MHz ultrasound probe with a sterile sheath cover was used to examine the occipital and suboccipital region and identify the subcutaneous tissue and paracervical muscles. After a small incision, a 14-gauge Tuohy style needle was advanced under live ultrasound guidance and adequate placement in the paracervical myofascial plane was confirmed in real-time. A percutaneous cylindrical 8-contact electrode was then advanced to the end of the Tuohy needle and held in place. Under live ultrasound visualization, the needle was removed, leaving the stimulator lead deep to the subcutaneous tissue and superficial to the paracervical muscles in the fascial plane. Fluoroscopy was then used to confirm lead placement along the internuchal/mastoid line connecting the occipital protuberance and mastoid process. Correct lead placement was further confirmed by visualizing the lead overlying the lateral mass (arch) of C1 at the interface of the C1-C2 zygapophyseal joint (12).

To anchor the stimulator lead, 2-wing plastic lead-anchor complexes were secured to the paravertebral fascia just proximal to the eighth electrode with 2-0 silk sutures. A strain-relief loop of approximately 5 cm was created for each lead and a second 2-wing plastic lead-anchor complex was secured and tightened with 2-0 silk sutures in a midline and slightly caudal location (Fig. 1). The above process was repeated on the contralateral side for bilateral lead placement procedures. A pocket for the internal pulse generator (IPG) was then created, nearly always in the flank (posterolateral spine). The leads were tunneled, and after confirmation of satisfac-

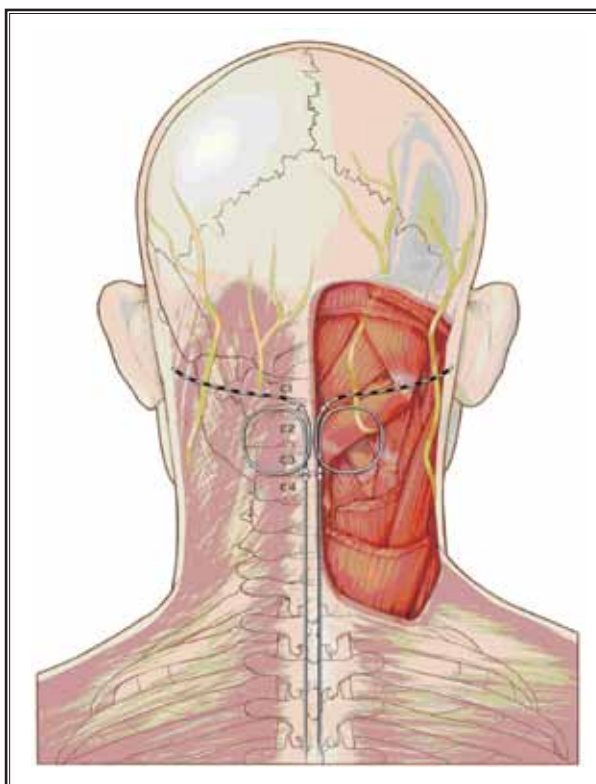


Fig. 1. Occipital nerve anatomy and bilateral ONS lead placement technique illustration. The left suboccipital region shows an intact aponeurosis and the right suboccipital region is a dissected view revealing the GON anatomy. The GON exists within a natural tissue plane between the semispinalis capitis and obliquus capitis inferior muscles and pierces the semispinalis capitis as it assumes a superficial course. The GON can be found within the trapezius muscle aponeurosis inferior to the internuchal line. Surgically, each lead is secured to the paravertebral fascia with 2 separate anchors and an inter-anchor tension relief loop. The final lead position is subcutaneous, roughly parallel to the internuchal line, superficial to the myofascial plane on ultrasound and visible at the C1-C2 articulation on fluoroscopy. Please note this figure is designed to be illustrative in nature.

tory lead connection and impedance check, the cervical incision and IPG pocket were sutured closed.

Analysis

The categorical variable of gender and continuous variables of age and follow-up time were recorded and the mean and standard deviation were reported. Reported dichotomized variables included placement of a strain-relief loop between 2 lead-anchor complexes, use of ultrasound guidance for lead placement, and

Table 1. ONS study cohort patient characteristics.

Patient	Age	Gender	Diagnosis	Tension Loop	Ultrasound guidance	Duration of Follow-up (months)
1	21	F	Occipital neuralgia	Yes	Yes	11
2	26	F	Intractable headache	Yes	Yes	14
3	29	M	Occipital neuralgia	Yes	Yes	25
4	33	F	Chronic Migraine	Yes	Yes	19
5	36	M	Chronic cluster headache	Yes	Yes	8.5
6	41	F	Chronic migraine	Yes	Yes	4
7	41	F	Intractable headache	Yes	Yes	16.5
8	42	F	Intractable headache	Yes	No	0.03 (1 day)
9	43	M	Chronic migraine	No	No	36
10	48	M	Occipital neuralgia	No	No	81
11	49	M	Chronic cluster headache	Yes	Yes	3
12	52	F	Occipital neuralgia	Yes	No	21
13	56	F	Occipital neuralgia	Yes	Yes	24
14	59	M	Intractable headache	Yes	No	1
15	63	M	Occipital neuralgia	Yes	Yes	6
16	64	F	Occipital neuralgia	Yes	Yes	19
17	64	M	Chronic cluster headache	Yes	Yes	10
18	71	M	Chronic cluster headache	Yes	Yes	2

M = male, F = female

adverse events, including lead migration, infection, etc. For clinical outcome variables, the continuous variables of pain levels using the NRS, headache days per week, and number of medications used to treat primary headache symptoms were recorded in both the preoperative and postoperative settings. The preoperative NRS pain score was the worst and most consistent NRS score given by the patient prior to implantation. The postoperative NRS pain score was the best and most consistent NRS score recorded over the duration of follow-up for that patient. Given the non-Gaussian distribution of these clinical outcome variables, non-parametric, Wilcoxon signed-rank tests were used to compare these continuous variables preoperatively and postoperatively for statistical significance (JMP Statistical Software, version 11, Cary, NC). Median and interquartile range (IQR) was reported for each clinical outcome variable. A *P*-value less than 0.05 was considered statistically significant.

RESULTS

Table 1 includes epidemiologic and procedure-related variables recorded in this study. Nine patients (50%) were men and 9 (50%) were women. Median (IQR) age was 45 (37 – 58) years (range 21 to 71 years) with a male age of 48 (43 – 60) and a female age of

41 (33 – 52) years. Twelve (67%) patients had bilateral headache symptoms, and of the 6 (33%) unilateral headache patients, 5 were left-sided and one was right-sided. The most common etiology for intractable headache in our cohort was occipital neuralgia, present in 7 (39%) patients. Non-classifiable but often occipital-predominant, intractable headache was present in 4 (22%) patients, chronic cluster headache in 4 (22%), and chronic migraine in 3 (17%).

For those with unilateral lead placement, the occipital leads coincided with their dominant headache phenotype (i.e., left-sided headaches received left-sided lead placement). Thirteen (72%) patients had documented use of ultrasound guidance for placement of the occipital leads, and 16 (89%) had evidence of a cervical region strain-relief loop using a double-point anchoring technique. Mean post-operative follow-up was 16.7 (\pm 18.8) months.

Table 2 provides a summary of adverse outcomes experienced in our patient cohort. Five (28%) patients experienced adverse events directly related to the ONS device or implantation. One (6%) patient experienced a battery malfunction requiring surgical battery replacement. One (6%) patient experienced a lead malfunction due to equipment failure or fracture, requiring surgical

Occipital Neuromodulation: A Surgical Technique with Reduced Complications

Table 2. ONS study cohort patient adverse events.

Adverse Event	Number of Patients	Surgical Revision	Comments
Lead position change ^a	1	No	* Clinically insignificant, illusion of motion could be artifact of fluoroscope positioning
Battery malfunction	1	Yes	* Replacement of battery due to expiration
Lead malfunction	1	Yes	* Left lead replacement due to poor paresthetic coverage
Infection	2	Yes	* 1 revision of cervical incision * 1 explantation without reimplantation

a: Not necessarily a lead migration and potentially not an adverse event

Table 3. ONS study cohort patient clinical outcomes.

Patient	Pre-Operative			Post-Operative		
	Pain	HA	Meds	Pain ^a	HA ^a	Meds ^a
1	9	7	2	1	1.5	0
2	4	2	3	1	2	2
3	7	7	1	2	2.5	0
4	9	3.5	8	6	1.5	6
5	10	7	4	2	1	5
6	10	NA	3	10	NA	4
7	7	7	4	3	7	2
8	9	NA	7	6	NA	7
9	7	7	5	7	7	4
10	10	7	3	0	0	2
11	9	7	3	4	1.5	3
12	8	7	2	0	0	1
13	10	NA	4	4	NA	2
14	10	7	2	0	0	2
15	10	7	1	1	1.5	0
16	10	7	4	0	0.5	3
17	10	2	3	3	0.25	3
18	10	7	3	5	1	3
Median (IQR)	9.5 (8.25 – 10)	7 (7 – 7)	3 (2.25 – 4)	2.5 (1 – 4.75)	1.5 (0.375 – 1.75)	2.5 (2 – 3.75)

Pain = numeric rating scale reported by patient and documented by provider

HA = number of days per week with primary headache disorder symptoms

Meds = number of oral medications used to treat primary headache disorder

NA = data not available

a: all observed reductions statistically significant

revision. There was concern for clinical infection in 2 patients (11%) due to poor wound healing, prompting one cervical incision revision and one complete explantation (this latter patient declined reimplantation given the risk for poor wound healing related to other medical comorbidities). In one (6%) patient, there was an electrode position change of less than one electrode length as documented by subsequent fluoroscopic evaluation. This finding could have been a result of dif-

ferent fluoroscope positioning or artifactual and was not necessarily representative of lead migration. There were no overt or equivocal signs of lead migration in any other case. One (6%) patient was lost to follow-up, but this was not counted among the surgical adverse events.

Table 3 demonstrates preoperative and postoperative patient reported outcomes. Following ONS implantation, NRS pain scores decreased from a median (IQR)

of 9.5 (8.25 – 10) to 2.5 (1 – 4.75) ($P < 0.0001$), headache days per week were reduced from 7 (7 – 7) to 1.5 (0.375 – 1.75) ($P = 0.0005$), and the number of oral medications used to treat headache declined from 3 (2.25 – 4) to 2.5 (2 – 3.75) ($P = 0.0112$). These reductions were all statistically significant.

Discussion

Occipital neuromodulation for the treatment of chronic, intractable primary headache disorders continues to show promising results but has unfortunately been associated with a number of complications (13-15). Lead migration is the most common adverse event and the reported frequency has varied substantially in the literature, with the largest migraine ONS RCTs reporting lead migration rates of 13.9% to 24% (7,16-17). The consequences of lead migration potentially entail a higher chance of stimulator inefficaciousness and the potential need for surgical revision, which could afford a host of additional potential complications. Currently, there is no guideline or outcome-based measure in practice to minimize lead migration. As a result, surgical technique is heterogeneous within and among ONS studies, potentially complicating research efforts to not only minimize adverse events, but also to maximize the potential of ONS for headache relief. This variability in surgical technique and the paucity of evidence-based literature in existence to study this phenomenon calls for further studies. Simple changes in procedural method and widespread standardization could potentially reduce lead migration, decrease patient morbidity, and increase the availability of ONS for a patient population that continues to experience suffering and disability.

Our data suggest that the use of a cervical strain-relief loop with 2 anchor-lead complexes placed prior to connecting the leads to the IPG may reduce the incidence of lead migration. Of those stimulators that were placed with a dual anchor-lead complex with strain-relief loop, only one (6%) had a lead position change that was not only clinically insignificant, but also quite possibly an artifact of fluoroscope positioning and not likely a lead migration in the first place. The documentation of migration is based principally on the perspective and angle of the x-ray, and a slight position change may be due to the intrinsic margin of error of this particular imaging modality. Despite the concern for lead migration, no surgical intervention was necessary in this case, and simple reprogramming of the IPG was performed to regain adequate paresthesia coverage. This pragmatic approach has shown reasonable

success before, sparing further surgical interventions and their attendant consequences (18).

Based on both early and more recent literature reviews, it appears that the most common surgical approach includes securing the anchor-lead complex to the fascia and making a “loop” with the lead prior to tunneling and connecting to the IPG (19,20). Others have even advocated forming more than one loop in the cervical fascia or along the path to the IPG, theorizing that this might decrease tension on the single lead-anchor complex and mitigate the likelihood for occipital lead migration (11,20). However, no one single practice is currently in place for anchoring of the occipital leads and, to our knowledge, the use of a dual anchor-lead complex with a tension-relief loop has not yet been described. The hypothesis that the fascial plane tissue will scar down and secure the occipital lead needs further study.

Based on our findings, we advocate placement of 2 lead-anchor complexes with a tension-relief loop of 5 cm in between the anchors prior to tunneling and IPG connection. This method would possibly lessen the tensile force applied directly to the proximal anchor closest to the occipital lead and potentially reduce the occurrence of lead migration. Arguably, a second-anchor point might also serve as an “insurance policy” if the first anchor were to fail, but there was no evidence of anchor failure as can best be ascertained by serial fluoroscopy. The placement of tension relief loops seems to be more common in the recent literature. A surgical technique employing a second tension relief loop has been previously shown to decrease the lead migration rate to 10%. However, this technique employed an additional incision and one of these patients suffered a surgical site infection (21). However, the lack of placing an additional anchor-lead complex after the loop could account for the continued high rates of lead migration.

Our data also suggest that the use of live ultrasound guidance for placement of the occipital lead is crucial to ensure that the lead is in the adequate tissue plane. Ultrasound use per se would not be associated with reduced lead migration rate since anchoring occurs at the fascial plane regardless of surgical technique, but it could be associated with increased efficacy. We have previously demonstrated that clearly identifying the soft tissue structures of the sub-occipital region with ultrasonography permits anatomically accurate placement of the lead along the inferior nuchal line in the fascial tissue plane

between the subcutaneous fat and the paravertebral muscle. As a result, we posit that the likelihood of ensuring adequate neuromodulation, patient safety, and procedural efficacy may be enhanced by the use of ultrasonography (12). Although fluoroscopy can be used to ensure lead placement along the inter-nuchal/inter-mastoid line, it cannot provide the degree of depth or tissue density discrimination to ensure that the lead is placed in the correct fascial plane. Improper placement of occipital leads can lead to poor parasthetic coverage, direct muscle stimulation, spasms, and discomfort. It has previously been shown that fluoroscopic lead placement at the inter-nuchal line as opposed to the more caudad C1-C2 interface may reduce painful muscle stimulation since the inter-nuchal line location contains a more superficial GON and more tendinous insertions as opposed to muscle bellies (22). However, this more superficial location at the inter-nuchal line may predispose to increased risk of lead erosion (23). Furthermore, ultrasound guidance may obviate the need for a rote, fluoroscopic-based implantation location by permitting dynamic GON and muscular visualization. Ultrasound accommodates for inherent patient variability and facilitates precise approximation to the GON without causing direct lead transgression through overlying musculature. Additionally, an exceptional understanding of cervico-occipital anatomy is essential to ensure precise lead placement and pre-empt the possibility of surgical complications and need for revision (16).

Lastly, our study joins others in suggesting that ONS lessens pain, reduces headache days per week, and decreases overall use of oral medication to treat headache pain. Although limited by our small sample size, we showed that ONS was associated with an NRS pain score reduction of 300% over an average 16 month follow-up, with 17 (94%) patients reporting a reduction in pain. ONS was also associated with a 300% reduction of headaches days per week and a 125% reduction in use of oral medications, all of which were statistically significant. Others have shown only a 53% reported response of significant pain relief, described as a > 50% reduction in frequency and intensity of headache attacks, although the longer follow-up period could have resulted in a fallout effect leading to the lower perceived benefit (14).

Our study is limited first and foremost by its retrospective design and investigator bias inherent to any single-center study. As a tertiary referral center, our patient population may also not necessarily reflect the

population at large. As our referral population tends to be medically complex with significant comorbidities, it is possible that our complication rate would in fact have been reduced and ONS efficacy magnified further in a more standard, less complex population. Limitations also include at times inconsistent operative report documentation of the use of ultrasound guidance and the true prevalence of ultrasound use in our series could have been understated. Additionally, obtaining the pre-operative and postoperative evaluation of pain levels, headache days per week, and use of oral medications to treat the primary headache pain was not standardized when evaluating patients and was not referenced to a control group. However, the primary purpose of the study was to investigate complication rates and not efficacy. Despite these limitations, we demonstrated dramatic clinical improvement similar to that of other ONS studies. Our heterogeneous headache pathology among ONS patients complicates interpretation of efficacy for any specific headache condition, but this study was designed to be descriptive and all-encompassing in nature.

With our surgical method, we demonstrated a lead migration rate of potentially 0%. If the lead position change noted above is counted, this number rises to 6%. This lead migration rate is significantly lower than that of most reported studies. The largest ONS in migraine RCTs reported lead migration rates between 13.9% and 24%, and the follow-up period in these studies ranged between 12 and 52 weeks. Our follow-up period was nearly 1.5 years. As a result, the lead migration complication rates published in other studies could have been even higher if the length of follow-up were extended. In a retrospective analysis of ONS spanning 8.5 years with a mean follow-up duration of 56 months, 58% of patients required at least one lead revision (1). Although our results are encouraging, more dedicated study of our surgical method is needed to ensure patient safety and maximize positive outcomes.

ONS has been endorsed by multiple physician societies, but it continues to remain an off-label treatment modality. We recommend that patients should fail multiple trials of standard headache medical therapies (both abortive and prophylactic strategies) prior to ONS consideration and call for further study of surgical methodology to decrease adverse events. We believe that adoption of our model of patient selection and surgical technique may benefit medically refractory headache patients and allow ONS to better succeed in the future.

CONCLUSION

The practice of occipital neuromodulation for medically intractable primary headache disorders has shown promise but is often limited by a high complication rate. We propose a combined utilization of ultrasound for lead placement and a dual anchor-lead complex technique with a tension-relief loop to facilitate excel-

lent paresthesia coverage and decrease the risk of lead migration, respectively. This technique was associated with an unprecedentedly lower complication rate of lead migration compared to previously reported rates while preserving the benefits of reduction in pain, headache days per week, and use of oral agents to control headache symptoms.

REFERENCES

- Brewer AC, Trentman TL, Ivancic MG, Vargas BB, Rebecca AM, Zimmerman RS, Rosenfeld DM, Dodick DW. Long-term outcome in occipital nerve stimulation patients with medically intractable primary headache disorders. *Neuromodulation* 2013; 16:557-564.
- Olesen J, Steiner TJ. The International classification of headache disorders, 2nd edition (ICDH-II). *J Neurol Neurosurg Psychiatry* 2004; 75:808-811.
- Natoli JL, Manack A, Dean B, Butler Q, Turkel CC, Stovner L, Lipton RB. Global prevalence of chronic migraine: A systematic review. *Cephalalgia* 2009; 30:599-609.
- Lipton RB, Bigal ME, Diamond M, Freitag F, Reed ML, Stewart WF. Migraine prevalence, disease burden, and the need for preventive therapy. *Neurol* 2007; 68:343-349.
- Lucado J, Paez K, Elixhauser A. *Headaches in U.S. hospitals and emergency departments, 2008*. HCUP statistical brief #111. Rockville, MD. Agency for Healthcare Research and Quality 2011; 1-12.
- Diamond S. *Headache and Migraine Biology and Management*. Academic Press, Boston, 2015, p 2.
- Chen YF, Bramley G, Unwin G, Hanu-Cernat D, Dretzke J, Moore D, Bayliss S, Cummins C, Lilford R. Occipital nerve stimulation for chronic migraine—a systematic review and meta-analysis. *PLoS one* 2015; 10:1-16.
- Dodick DW, Silberstein SD, Reed KL, Deer TR, Slavin KV, Huh B, Sharan AD, Narouze S, Mogilner AY, Trentman TL, Ordia J, Vaisman J, Goldstein J, Mekhail N. Safety and efficacy of peripheral nerve stimulation of the occipital nerves for the management of chronic migraine: Long-term results from a randomized, multicenter, double-blinded, controlled study. *Cephalalgia* 2014; 0:1-15.
- Martelletti P, Jensen RH, Antal A, Arcioni R, Brighina F, de Tommaso M, Franzini A, Fontaine D, Heiland M, Jürgens TP, Leone M, Magis D, Paemeleire K, Palmisani S, Paulus W, May A. Neuromodulation of chronic headaches: Position statement from the European Headache Federation. *J Headache Pain* 2013; 14:1-16.
- Sweet JA, Mitchell LS, Narouze S, Sharan AD, Falowski SM, Schwab JM, Machado A, Rosenow JM, Petersen EA, Hayek SM, Arle JE, Pilitsis JG. Occipital nerve stimulation for the treatment of patients with medically refractory occipital neuralgia: Congress of Neurological Surgeons systematic review and evidence-based guideline. *Neurosurg* 2015; 77:32-34.
- Sloty PJ, Bara G, Vesper J. The surgical technique of occipital nerve stimulation. *Acta Neurochir* 2015; 157:105-108.
- Eldridge JS, Obray JB, Pingree MJ, Hoelzer BC. Occipital neuromodulation: Ultrasound guidance for peripheral nerve stimulator implantation. *Pain Pract* 2010; 10:580-585.
- Saper JR, Dodick DW, Silberstein SD, McCarville S, Sun M, Goadsby PJ. Occipital nerve stimulation for the treatment of intractable chronic migraine headache: ONSTIM feasibility study. *Cephalalgia* 2011; 31:271-285.
- Palmisani S, Al-Kaisy A, Arcioni R, Smith T, Negro A, Lambro G, Bandikatla V, Carson E, Martelletti P. A six year retrospective review of occipital nerve stimulation practice-controversies and challenges of an emerging technique for treating refractory headache syndromes. *J Headache Pain* 2013; 14:1-10.
- Jürgens TP, Leone M. Pearls and pitfalls: Neurostimulation in headache. *Cephalalgia* 2013; 33:512-525.
- Zimmerman RS, Rosenfeld DM, Freeman JA, Rebecca AM, Trentman TL. Revision of occipital nerve stimulator leads: Technical note of two techniques. *Neuromodulation* 2011; 15:387-391.
- Hann S, Sharan A. Dual occipital and supraorbital nerve stimulation for chronic migraine: A single-center experience, review of literature, and surgical considerations. *Neurosurg Focus* 2013; 35:1-8.
- Magis D, Allena M, Bolla M, De Pasqua V, Remacle JM, Schoenen J. Occipital nerve stimulation for drug-resistant chronic cluster headache: A prospective pilot study. *Lancet Neurol* 2007; 6:314-321.
- Trentman TL, Zimmerman RS. Occipital nerve stimulation: Technical and surgical aspects of implantation. *Headache* 2008; 48:319-327.
- McGreevy K, Hameed H, Erdek MA. Updated perspectives on occipital nerve stimulator lead migration case report and literature review. *Clin J Pain* 2012; 28:814-818.
- Falowski S, Wang D, Sabesan A, Sharan A. Occipital nerve stimulator systems: Review of complications and surgical techniques. *Neuromodulation* 2010; 13:121-125.
- Relief C, Virginia W, Hayek SM. Occipital neurostimulation-induced muscle spasms: Implications for lead placement. *Pain Physician* 2009; 12:867-876.
- Trentman TL, Dodick DW, Zimmerman RS, Birch BD. Percutaneous occipital stimulator lead tip erosion: Report of 2 cases. *Pain Physician* 2008; 11:253-256.