

# Occipital Nerve Stimulator Placement via a Retromastoid to Infraclavicular Approach: A Technical Report

Terrence L. Trentman<sup>a</sup> Konstantin V. Slavin<sup>d</sup> John A. Freeman<sup>b</sup>  
Richard S. Zimmerman<sup>c</sup>

Departments of <sup>a</sup>Anesthesiology, <sup>b</sup>Physical Medicine and Rehabilitation and <sup>c</sup>Neurosurgery, Mayo Clinic Arizona, Phoenix, Ariz., and <sup>d</sup>Department of Neurosurgery, University of Illinois at Chicago, Chicago, Ill., USA

## Key Words

Occipital nerve stimulator · Retromastoid · Infraclavicular region

## Abstract

Occipital nerve stimulation is a form of peripheral nerve stimulation used to treat refractory headache disorders. Various techniques have been described for occipital nerve stimulator implantation; these include midline cervical or retromastoid lead insertion with internal pulse generator placement in the infraclavicular, gluteal or low abdominal regions. Lead migration is one of the most common complications of occipital nerve stimulators. Implantation approaches that include remote battery sites may contribute to mechanical stress on the components, as the leads or extensions may traverse highly mobile body regions. In this technical report, we describe an occipital stimulator implantation technique that may be advantageous in terms of patient positioning, ease of surgical approach and minimization of mechanical stress on components.

Copyright © 2010 S. Karger AG, Basel

## Introduction

Occipital nerve stimulation (ONS) is a form of peripheral nerve stimulation used to treat refractory headache disorders. A growing body of literature describes benefit of this technique for patients suffering from cluster headache [1, 2], migraine [3–5], occipital neuralgia [6, 7], post-surgical pain [8] and hemicrania continua [9, 10]. However, complications have also been reported [10, 11]. Prospective, blinded outcome studies are underway that may support Food and Drug Administration approval of this modality [12]. Until such time that Food and Drug Administration approval is granted, ONS will remain an off-label use of spinal cord stimulation equipment.

At least 2 techniques have been described for ONS implantation: from a midline cervical [1, 5–7, 10, 13, 14] or retromastoid approach [2, 3, 15–18]. From either the midline cervical or retromastoid site, the leads and extension cables (if needed) can be tunneled to an internal pulse generator (IPG) in the infraclavicular, buttock or low abdominal site. Anecdotally, we are also aware of IPGs being placed in the infra-axillary region.

Patients who initially experience effective occipital region stimulation with associated headache relief may

**Table 1.** Sequence of steps for ONS placement from a retromastoid approach

1	Positioning: supine with head turned maximally away from the infraclavicular site chosen for IPG placement (fig. 1)
2	Fluoroscopy: in the AP plane to identify the C1 level and allow the implanter to stand 'in the C' (fig. 2)
3	Incisions: retromastoid (2.5 cm) and midline (<1 cm) at C1 level
4	Dependent lead tunneling: lead inserted via a slightly curved needle from midline incision toward dependent mastoid process (fig. 3); the needle is removed (fig. 4), and the needle stylet is inserted from the midline incision into the retromastoid incision; the Touhy needle is passed over the stylet (fig. 5) and the stylet is removed; the lead is passed through the needle from midline to lateral (fig. 6)
5	Nondependent lead insertion: via a slightly curved needle from the retromastoid incision towards the midline; both leads are anchored in the retromastoid pocket (fig. 7)
6	Lead testing: assess symmetry of leads with fluoroscopy (fig. 8) and test current of up to 10 A in each lead while watching for direct muscle stimulation
7	Anchor leads and tunnel to internal pulse generator; interrogate system to insure normal impedance before final closure

suddenly note a loss of stimulation. This stimulation failure may be due to lead fracture or battery depletion, but in our experience it is most often secondary to lead migration [10]. The etiology of lead migration (lead movement that results in ineffective stimulation) is not fully understood, but certainly the repeat mechanical stresses applied to the components of an ONS system play a role. Depending on the approach to ONS implantation, the leads and extension cables may traverse highly mobile body regions including the neck and thorax.

The IPG site selected also influences the patient position during surgery. A gluteal IPG allows easy tunneling from neck to buttock with the patient in the prone position, while infraclavicular or low abdominal sites necessitate a lateral patient position. Our experience suggests that the gluteal region is associated with much greater stress on the lead due to the highly mobile low back, when compared to low abdomen or infraclavicular sites. The patient position has implications for anesthesia management including choice of airway and the time necessary for patient preparation in the operating room.

The purpose of this technical report is to describe a method for ONS implantation that combines simple patient positioning (supine), short tunneling distance (from

retromastoid to infraclavicular) and minimal mechanical stress on the components (avoidance of highly mobile body regions including midline cervical and low back). This report is an expansion upon the technique described previously by Slavin et al. [18].

### Description of Technique

The goal of lead insertion is to achieve symmetrical occipital region stimulation via leads placed transversely in the epifascial plane at approximately the C1 or intermastoid level. The leads are both introduced from a single retromastoid region, but 1 lead will cross the midline. Lead insertion that is too deep may result in painful direct muscle stimulation, while too superficial placement may predispose the patient to lead erosion [11] (table 1).

#### Positioning

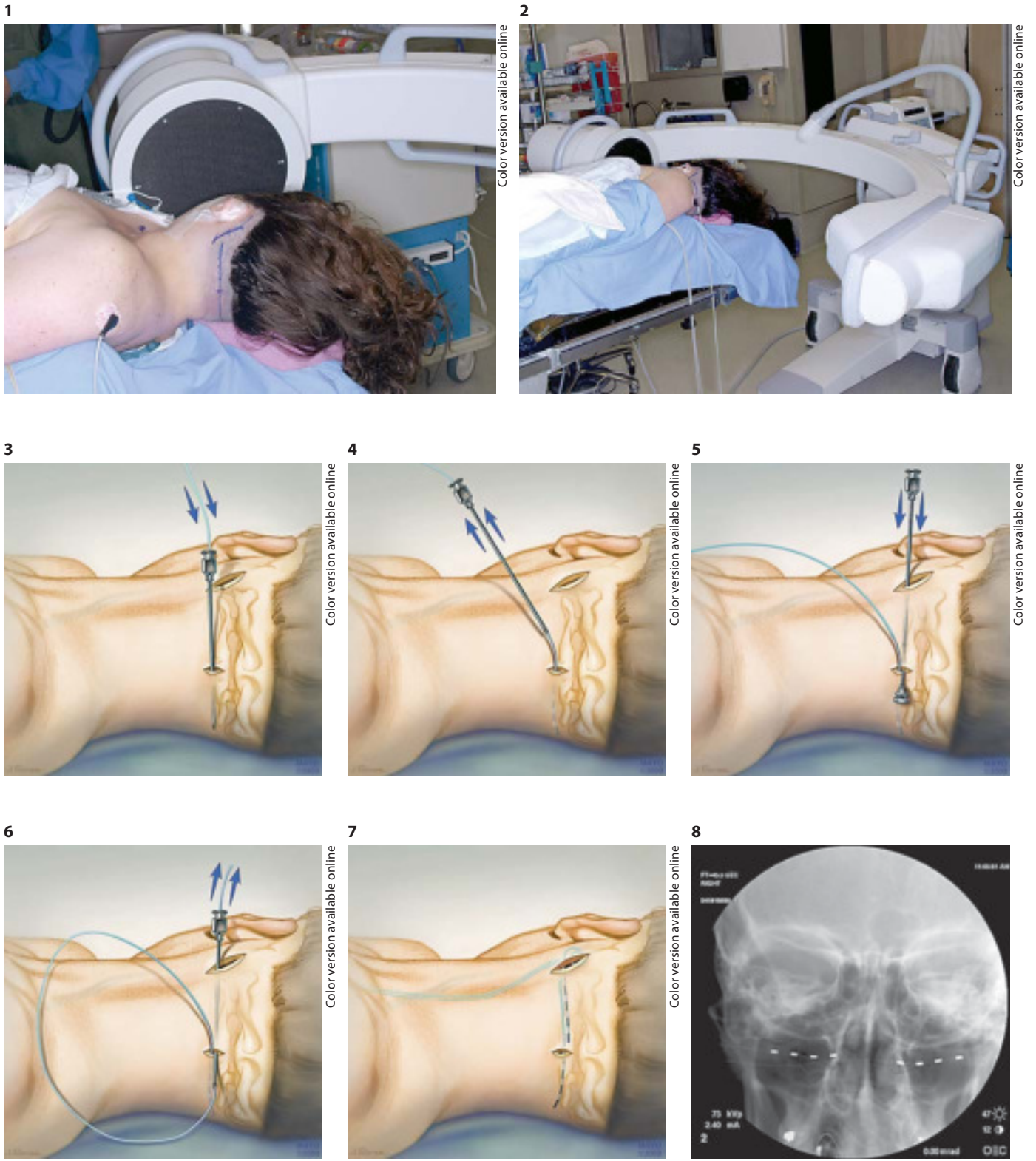
After occipital region 'clipper' shave and antibiotic prophylaxis, the patient is placed in the supine position. For trial insertion of ONS leads, the procedure can be performed under conscious sedation. We use general anesthesia without muscle relaxation for permanent implantation. This allows easier and safer tunneling of the leads through the neck in a still patient while also enabling us to check for direct muscle stimulation.

For either trial or permanent lead insertion, the patient's head is turned maximally away from the infraclavicular side chosen for IPG insertion (fig. 1). The head is placed on a small cushion that lifts it enough to allow access to the dependent occipital region. For our purposes, the dependent occipital region and mastoid process is defined as the areas closest to the operating room table and opposite the side chosen for the retromastoid incision. A small wedge is placed under the ipsilateral shoulder.

The sterile field includes the neck and upper chest on the ipsilateral side (permanent implant) and importantly the dependent occipital region. It is vital that this area is not covered in sterile drapes so the implanter can palpate the needle subcutaneously. This helps insure the dependent needle is not too superficial including through the skin. A slight bend, meant to approximate the curvature of the occipital region, is applied to the 14-gauge Touhy needle.

#### Fluoroscopy

Fluoroscopy in the anterior-posterior (AP) plane is used to identify the C1 level. A straight-AP fluoroscopic



**Fig. 1–8.** ONS placement procedure.

view is assumed when the dens is visible transecting the nasal septum. The C arm approaches the patient from the head of the bed, thus allowing the implanter to stand 'in the C' during the procedure (fig. 2).

### *Incisions*

A 2.5-cm retromastoid incision is made along the hairline. The tissue is dissected to the fascia and hemostasis is insured. The tissue lateral to the incision is undermined to create a pocket for anchoring of the leads and a stress relief loop. Next, a small incision (<1 cm) is made in the midline at the C1 level, through which the Touhy needle is advanced toward the dependent mastoid process (fig. 3). When the needle is advancing in the epifascial fat, it moves with relative ease, whereas the fascia or dermis produces much more resistance. A lateral needle tip position is not worrisome at this point because the lead can easily be withdrawn later toward the midline. The stylet is removed and a quadripolar or octopolar lead is inserted through the dependent Touhy, which is then removed (fig. 4). The stylet is then inserted from the midline incision toward the nondependent retromastoid incision, and the Touhy needle is passed over the stylet from lateral to medial (fig. 5).

### *Dependent Lead Tunneling*

The stylet is removed and the lead is passed through the Touhy needle (fig. 6). Hence, the dependent lead has been tunneled across the midline to the retromastoid incision via a 'needle-over-stylet' technique, where it will be anchored. Next, the nondependent lead is inserted from the retromastoid incision towards the midline, taking care to avoid the dependent lead (fig. 7). Alternatively, the nondependent lead can be inserted while the dependent stylet is in place, before tunneling the dependent lead. This insures the dependent lead is protected from needle trauma.

### *Lead Testing*

Once both leads are in place, fluoroscopy is used to assess symmetry (fig. 8). Frequently, the dependent lead needs to be pulled toward the midline, and the nondependent lead is pulled toward the retromastoid incision. At this point, the leads are tested to insure no direct muscle stimulation is observed. A current up to 10 A at low frequency is programmed through each lead and the cervical paraspinal region is observed for twitch. If any muscle movement occurs, the lead is assumed to be too deep, perhaps through the fascia, and it is repositioned.

### *Lead Anchoring and Tunneling to the Generator*

The leads are then affixed to the retromastoid fascia using anchors provided and nonabsorbable suture. Although we are unaware of any published data to support its practice, the lead-anchor interface can also be reinforced with silicone glue in an effort to minimize the migration risk. Finally, the leads are tunneled to the subcutaneous infraclavicular IPG pocket. In most cases, a lead of sufficient length can be selected that obviates the need for an extension cable. The ONS is interrogated for impedance to insure that all components are intact, and the incisions are closed in layers following hemostatic inspection and antibiotic solution irrigation.

## **Discussion**

Occipital nerve stimulation may offer headache relief and functional improvement to patients otherwise suffering from refractory pain. This report, as an expansion of the original description by Slavin [18], describes a surgical approach to ONS placement that has potential advantages in terms of patient positioning, tunneling distance and avoidance of highly mobile body regions. The use of fluoroscopy as described, with the surgeon standing 'in the C,' should allow simple and rapid lead placement and assessment for position and symmetry. Simplified patient positioning and fluoroscopy use may also contribute to more efficient operating room utilization. Although prospective data are lacking, this technique may result in fewer mechanical ONS complications including lead migration.

The existing literature includes a few descriptions of ONS insertion technique. Weiner and Reed [15] reintroduced ONS in 1999 and mention several approaches, including midline cervical or retromastoid insertion with IPGs in the buttock, abdominal, flank or subclavicular regions. They also describe using a single lead positioned with electrodes on either side of the midline. Oh et al. [3] report inserting paddle leads from a retromastoid approach for occipital neuralgia, with the IPG in an infraclavicular site. For transformed migraine, they describe insertion of bilateral leads from a midline occipital incision and battery placement in the buttock.

The outcome with ONS and surgical techniques have lately been reviewed [19, 20]. We have recently reported on the use of a microstimulator for ONS, although this device is not currently commercially available [21]. If ONS is found to be an effective headache modality, microstimulators may offer patients occipital stimulation



without the need for lead tunneling and IPG insertion. Until that time, spinal cord stimulator components will continue to be adapted for headache management.

Lead migration is not unique to ONS. Migration of leads, component fracture and erosion have been reported with spinal cord stimulators as well [22]. The low back is highly mobile; tunneling of ONS or spinal cord stimulator leads to the gluteal region may place more stress on components than an abdominal IPG site.

Disadvantages of our technique are several. Cosmetically, patients may find the infraclavicular IPG site undesirable [23]. The retromastoid to infraclavicular pathway is reminiscent of that used for tunneling a ventriculoperitoneal shunt; potentially, a pathway from retromastoid to low abdomen could be used, although we have not applied this approach. Tunneling of leads through the high-

ly vascular cervical region may place the patient at risk for bleeding complications. Theoretically, both leads could be inserted via the retromastoid approach without the midline incision. This would require a longer needle (or trochar) than the one provided in the kit. Special care would be needed to avoid too deep or superficial lead placement along the pathway from retromastoid incision to contralateral side. We have not attempted this approach.

In conclusion, we have described a retromastoid to infraclavicular ONS implantation technique that may be advantageous in terms of patient positioning, ease of surgical approach and minimizing mechanical stress on components. Longitudinal studies may better clarify the best surgical approaches for this challenging form of peripheral nerve stimulation.

## References

- 1 Burns B, Watkins L, Goadsby PJ: Treatment of medically intractable cluster headache by occipital nerve stimulation: long-term follow-up of eight patients. *Lancet* 2007;369:1099–1106.
- 2 Magis D, Allena M, Bolla M, De Pasqua V, Remacle JM, Schoenen J: Occipital nerve stimulation for drug-resistant chronic cluster headache: a prospective pilot study. *Lancet Neurol* 2007;6:314–321.
- 3 Oh MY, Ortega J, Bellotte JB, Whiting DM, Alo KM: Peripheral nerve stimulation for the treatment of occipital neuralgia and transformed migraine using a C1-2-3 subcutaneous paddle style electrode: a technical report. *Neuromodulation* 2004;7:103–112.
- 4 Rogers LL, Swidan S: Stimulation of the occipital nerve for the treatment of migraine: current state and future prospects. *Acta Neurochir Suppl* 2007;97:121–128.
- 5 Popeney CA, Alo KM: Peripheral neurostimulation for the treatment of chronic, disabling transformed migraine. *Headache* 2003;43:369–375.
- 6 Johnstone CS, Sundaraj R: Occipital nerve stimulation for the treatment of occipital neuralgia – eight case studies. *Neuromodulation* 2006;9:41–47.
- 7 Kapural L, Mekhail N, Hayek SM, Stanton-Hicks M, Malak O: Occipital nerve electrical stimulation via the midline approach and subcutaneous surgical leads for treatment of severe occipital neuralgia: a pilot study. *Anesth Analg* 2005;101:171–174.
- 8 Ghaemi K, Capelle HH, Kinfe TM, Krauss JK: Occipital nerve stimulation for refractory occipital pain after occipitocervical fusion: expanding indications. *Stereotact Funct Neurosurg* 2008;86:391–393.
- 9 Schwedt TJ, Dodick DW, Trentman TL, Zimmerman RS: Occipital nerve stimulation for chronic cluster headache and hemicrania continua: pain relief and persistence of autonomic features. *Cephalalgia* 2006;26:1025–1027.
- 10 Schwedt TJ, Dodick DW, Hentz J, Trentman TL, Zimmerman RS: Occipital nerve stimulation for chronic headache – long-term safety and efficacy. *Cephalalgia* 2007;27:153–157.
- 11 Trentman TL, Dodick DW, Zimmerman RS, Birch BD: Percutaneous occipital stimulator lead tip erosion: report of two cases. *Pain Physician* 2008;11:253–256.
- 12 <http://clinicaltrials.gov/ct2/results?term=occipital+nerve+stimulation> (last accessed 6/16/2009).
- 13 Jones RL: Occipital nerve stimulation using a medtronic resume II electrode array. *Pain Physician* 2003;6:507–508.
- 14 Rodrigo-Royo MD, Azcona JM, Quero J, Lorente MC, Acin P, Azcona J: Peripheral neurostimulation in the management of cervicogenic headache: four case reports. *Neuromodulation* 2005;8:241–248.
- 15 Weiner RL, Reed KL: Peripheral neurostimulation for the control of intractable occipital neuralgia. *Neuromodulation* 1999;2:217–221.
- 16 Hammer M, Doleys DM: Perineuronal stimulation in the treatment of occipital neuralgia: a case study. *Neuromodulation* 2001;4:47–51.
- 17 Slavin KV, Colpan ME, Munawar N, Wess C, Nersesyan H: Trigeminal and occipital peripheral nerve stimulation for craniofacial pain: a single-institution experience and review of the literature. *Neurosurg Focus* 2006;21:1–5.
- 18 Slavin KV, Nersesyan H, Wess C: Peripheral neurostimulation for treatment of intractable occipital neuralgia. *Neurosurgery* 2006;58:112–119; discussion 112–119.
- 19 Jasper JF, Hayek SM: Implanted occipital nerve stimulators. *Pain Physician* 2008;11:187–200.
- 20 Trentman TL, Zimmerman RS: Occipital nerve stimulation: technical and surgical aspects of implantation. *J Head Face Pain* 2008;48:319–327.
- 21 Trentman TL, Rosenfeld DM, Vargas BB, Schwedt TJ, Zimmerman RS, Dodick DW: Greater occipital nerve stimulation via the bion microstimulator: implantation technique and stimulation parameters. *Clinical trial: Nct00205894*. *Pain Physician* 2009;12:621–628.
- 22 Rainov NG, Heidecke V: Hardware failures in spinal cord stimulation (SCS) for chronic benign pain of spinal origin. *Acta Neurochir Suppl* 2007;97:101–104.
- 23 Syed M, Slavin KV: Infraclavicular generator placement for neurostimulation: are the patients satisfied?; in Krames E, Meglio M (eds): 7th Meeting of the International Neuromodulation Society. Rome, 2005, pp 81–84.